Pain Physician 2016; 19:E1035-E1040 • ISSN 2150-1149

Retrospective Study

Contrast Runoff Correlates with the Clinical Outcome of Cervical Epidural Neuroplasty Using a Racz Catheter

Yun-Joung Han, MD, Myoung No Lee, MD, Min Ji Cho, MD, Hue Jung Park, MD, PhD, Dong Eon Moon, MD, PhD, and Young Hoon Kim, MD, PhD

From: Seoul St. Mary's Hospital, College of Medicine, The Catholic University of Korea

Address Correspondence:
Young Hoon Kim, MD, PhD
Assistant professor
Seoul St. Mary's Hospital, College of Medicine, The Catholic University of Korea
Department of Anesthesiology and Pain Medicine
222 Banpo-daero, Seocho-gu
Seoul, 137-701
Korea
E-mail:
anekyh@catholic.ac.kr

Disclaimer: There was no external funding in the preparation of this manuscript.
Conflict of interest: Each author certifies that he or she, or a member of his or her immediate family, has no commercial association (i.e., consultancies, stock ownership, equity interest, patent/licensing arrangements, etc.) that might pose a conflict of interest in connection with the submitted manuscript.

Manuscript received: 12-29-2015
Revised manuscript received: 03-09-2016
Accepted for publication: 03-29-2016

Free full manuscript:
www.painphysicianjournal.com

Background: Epidural neuroplasty using a Racz catheter has a therapeutic effect. Studies have found no correlation between foraminal stenosis and the outcome of epidural neuroplasty, which is thought to depend on contrast runoff.

Objective: To examine the correlation between the contrast spread pattern and pain reduction in cervical epidural neuroplasty using a Racz catheter.

Study Design: Retrospective study.

Setting: An interventional pain-management practice in a university hospital.

Methods: Fluoroscopic images were reviewed retrospectively. The spread of contrast from the neural foramen to a nerve root was called contrast runoff. If the contrast did not spread in this manner, then there was no contrast runoff. We defined successful epidural neuroplasty as a 50% or greater reduction from the pre-procedure numeric rating scale (NRS) score for total pain, and an at least 40% reduction in the neck pain and disability scale (NPDS) score.

Results: This study reviewed 169 patients. Among the patients who had a contrast runoff pattern, the epidural neuroplasty was rated as successful in 96 (74.4%), 97 (75.2%), 86 (66.7%), and 79 (61.2%) cases one, 3, 6, and 12 months after the procedure, respectively. When there was no contrast runoff, the epidural neuroplasty was successful in 12 (30%), 12 (30%), 10 (25%), and 10 (25%) cases at one, 3, 6, and 12 months after the procedure ($P < 0.001$). Logistic regression of the contrast spread pattern and predicting successful epidural neuroplasty gave similar results. Patients with a contrast runoff pattern had odds ratios of 6.788, 7.073, 6.000, and 4.740 at one, 3, 6, and 12 months, respectively ($P < 0.001$).

Limitations: This study lacked a control group, and the patients were not classified by their diagnosed disease, such as spinal stenosis, herniated nucleus pulposus, and post-spinal surgery syndrome.

Conclusions: Cervical epidural neuroplasty with a contrast runoff pattern had a higher success rate. Contrast runoff should be observed during neuroplasty, even in the presence of foraminal stenosis.

Key words: Cervical spinal pain, contrast, contrast runoff, epidural neuroplasty, percutaneous adhesiolysis, Racz catheter

Pain Physician 2016; 19:E1035-E1040

Various studies have shown the therapeutic effects of cervical epidural steroid injection. Cervical epidural steroid injections are widely administered to patients with cervical disc herniation or spinal stenosis (1). Moon et al (2) also demonstrated the effectiveness of cervical epidural neuroplasty, and reported factors associated with unsuccessful outcomes. Park et al (3) reported no statistically significant correlation between pain relief and severity of cervical central stenosis after percutaneous adhesiolysis using a Racz catheter. Although previous studies found no correlation between foraminal stenosis and the outcome of epidural neuroplasty, differences in the contrast spread pattern are clearly evident. The advantage of injecting cervical epidural steroid via a catheter is that this method allows delivery of the injectate adjacent to the target lesion. However, adjacent delivery of injectate does not necessarily signify flow of the injectate through the target lesion and foramen. Therefore, this study examined the correlation between the contrast spread pattern and pain reduction in cervical epidural neuroplasty using a Racz catheter.

Methods

This study was approved by the Institutional Review Board of Seoul St. Mary's Hospital, the Catholic University of Korea (IRB No. KC15RISI0368).

Participants

We retrospectively enrolled 169 patients with chronic posterior neck and upper extremity pain who did not respond to cervical epidural steroid injections. As the next stage of treatment, cervical epidural neuroplasty using a Racz catheter was performed. The patient's symptoms, neurological examination, and imaging studies were evaluated to make a diagnosis. Patients 20 to 80 years old with a herniated disc, spinal stenosis, or post cervical surgery syndrome were included. Cervical epidural neuroplasty using a Racz catheter was done, and patients had regular follow-up visits until 12 months after the neuroplasty. This study was carried out for 3 years, and 169 consecutive patients were reviewed.

Epidural Neuroplasty

Patients were positioned prone, and draped in a sterile manner. With 1% lidocaine, the skin was infiltrated, and an 18-gauge 3½-inch epidural needle (RX epidural needle, Coudé; Epimed International, Johnstown, NY) was inserted at the level of T1-T2 intervertebral space under fluoroscope. A needle was advanced to the epidural space with the needle tip facing in the caudal direction. The epidural space was confirmed by loss-of-resistance, and the tip of the needle was rotated to the cephalad direction. To prevent dural puncture, the RX-2 Coudé needle has a second stylet which protrudes beyond the tip of the needle. An epidural catheter was inserted through the needle, and advanced to the lateral part of the targeted lesion. Lateral positioning of the catheter was intended for the spread into both the anterior and posterior epidural space. Oh et al (4) stated that in percutaneous epidural neuroplasty in the lumbar spine, the catheter tip at the ventral position had a better outcome. The targeted lesion was determined by magnetic resonance imaging (MRI) findings, and the location of the catheter was confirmed under fluoroscope using 0.5 – 1 mL of contrast media. When epidurogram without intravascular or subarachnoid filling was confirmed, 1,500 units of hyaluronidase in 2 mL preservative-free normal saline were injected via epidural catheter. Injection of 2 mL of 0.125% bupivacaine and 5 mg of triamcinolone mixture followed. After the injection of these injectates, perivenous counterspread could occur, which is a dangerous warning sign of loculation. It could compress the blood supply from the spinal cord causing pain, and leading to possible spinal cord injury (5). Pain can be relieved by neural flossing, a repeated movement of flexion rotation from the chin to both shoulders. With neural flossing, lateral transforaminal contrast runoff is present under fluoroscope (Fig. 1). Perivenous counter spread, which is a dangerous warning sign, can be found from loculation. Thorough examination of the fluoroscopic image is indispensable.

Two-milliliters of 10% sodium chloride solution were infused over 30 minutes at 30 minutes after the procedure. During the infusion, vital signs and neurologic change were monitored. On a day after the procedure, patients received another 30 minute-infusion of 2 mL of 0.125% bupivacaine and 2 mL of 10% sodium chloride solution. The epidural catheter was removed after the infusion. The entire procedure was carried out by 2 pain physicians with more than 10 years of experience in the field.

Clinical Evaluations

Patients evaluated their symptoms by completing questionnaires before and one, 3, 6, and 12 months after the procedure. Success was defined as a 50% or

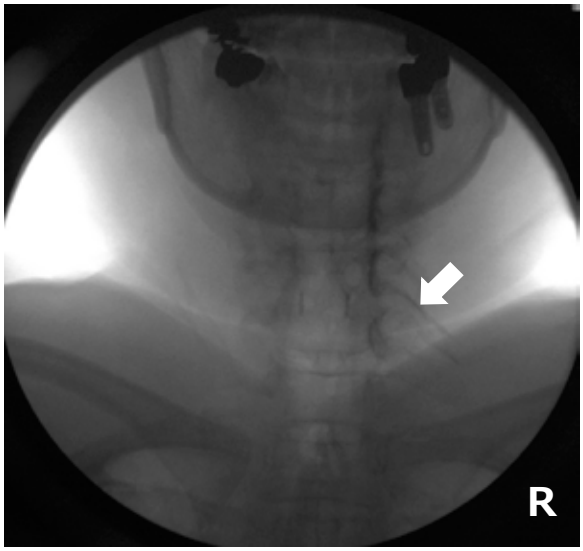

Fig. 1. *Contrast runoff of right C5 nerve after neural flossing. White arrow indicates right C5 nerve.*

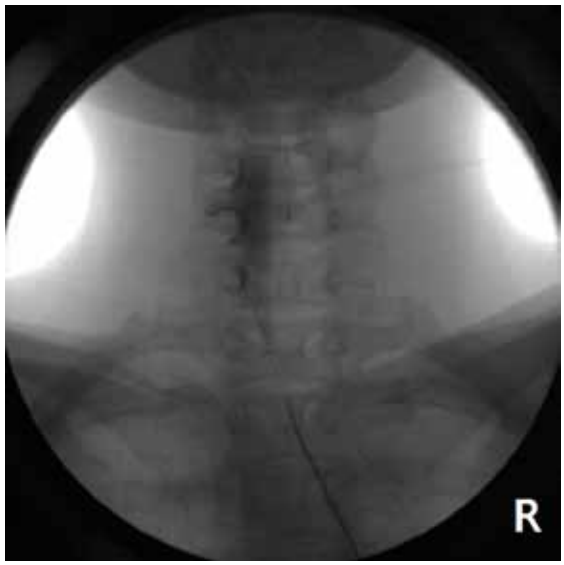

Fig. 2. *Cervical epidural neuroplasty with contrast runoff.*

greater reduction in pain score on the pre-procedural numeric rating scale (NRS), and an at least 40% reduction in score on the Korean version of the Neck Pain and Disability Scale (NPDS) (6). The total NRS, neck pain, and arm pain scores were recorded along with the NPDS score.

The fluoroscopic images taken during cervical epidural neuroplasty were reviewed. An anteroposterior view of the cervical spine was obtained using 0.5 – 1 mL of contrast medium, after injecting hyaluronidase and bupivacaine. At the end of the procedure, a final fluoroscopic image was taken. When contrast spread out from the neural foramen, flowing past the dorsal root ganglion, the pattern was considered as contrast runoff (Fig. 2). If the contrast did not spread out of the neural foramen, contrast runoff was deemed to be absent (Fig. 3). These images were examined by 2 clinicians who were involved with the procedure.

Statistical Analysis

The chi-square test was used to compare the contrast spread pattern and procedure outcome. The correlation between successful cervical epidural neuroplasty and contrast spread pattern was analyzed using logistic regression analysis. The statistical analysis was performed using SPSS for Windows software (ver. 18.0; SPSS Inc., Chicago, IL). A P-value < 0.05 was considered statistically significant.

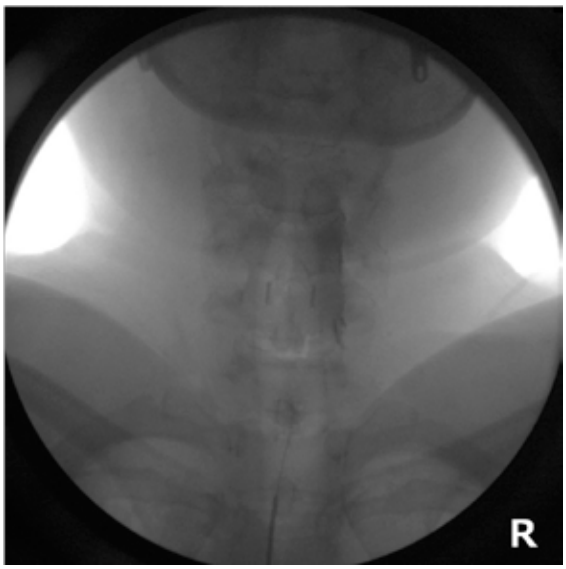

Fig. 3. *Cervical epidural neuroplasty of right C5 nerve without contrast runoff.*

Results

The 169 patients reviewed included 95 women and 74 men with a mean symptom duration of 51.5 ± 54.7 months. The diagnoses were spinal stenosis (118 patients, 69.8%), herniated disc (32 patients, 18.9%), and post cervical surgery syndrome (19 patients, 11.2%).

Before visiting our clinic, 46 patients (27.2%) received a recommendation for surgery (Table 1).

Among the patients with a contrast runoff pattern, the epidural neuroplasty was rated successful in 96 (74.4%), 97 (75.2%), 86 (66.7%), and 79 (61.2%) cases, one, 3, 6, and 12 months after the procedure, respectively. In comparison, in the patients with no contrast runoff, the epidural neuroplasty was successful in 12 (30%), 12 (30%), 10 (25%), and 10 (25%) cases, one, 3, 6, and 12 months after the procedure, respectively ($P < 0.001$; Table 2). Foraminal stenosis was found in 88 patients, of whom 56 (63.6%) showed contrast runoff. Among the 56 patients, the outcome was rated as successful in 43 (76.8%), 43 (76.8%), 36 (64.3%), and 33 (58.9%) cases, one, 3, 6, and 12 months after the procedure, respectively (Table 3). The logistic regression between the contrast spread pattern and predicting successful epidural neuroplasty gave similar results ($P < 0.001$; Table 4).

Table 1. *Characteristics of patients.*

Characteristic		n = 169
Age (years)		51.7 ± 10.5
Sex (female/male)		95/74
Duration of Symptoms (months)		51.5 ± 54.7
Diagnosis	Herniated Disc	32 (18.9)
	Spinal Stenosis	118 (69.8)
	Post Cervical Surgery Syndrome	19 (11.2)
Recommendations for Surgery		46 (27.2)
MRI Grade Of Cervical Canal Stenosis	Grade 0	0 (0)
	Grade 1	81 (47.9)
	Grade 2	77 (45.6)
	Grade 3	11 (6.5)
Spondylolisthesis		23 (13.6)
Foraminal Stenosis		88 (52.1)
OPLL		11 (6.5)

Data represent the mean ± SD, number or frequency (percentage). OPLL = ossification of posterior longitudinal ligament, SD = standard deviation.

Discussion

Cervical epidural neuroplasty has a therapeutic effect in patients with chronic posterior neck and upper extremity pain due to cervical central stenosis (3). It has shown to be effective in the lumbar spine also (7,8). Patients that have undergone surgery or have spondylolisthesis or ossification of the posterior longitudinal ligament are more likely to have unsuccessful outcomes (2), whereas the presence of foraminal stenosis does not affect the clinical outcomes (2,9). We observed a higher success rate when contrast runoff was seen, even in patients with foraminal stenosis.

Park and Lee (9) found no correlation between the therapeutic response to cervical transforaminal steroid injection and contrast dispersion pattern, and concluded that direct access to the nerve root is not essential, although there were some limitations to their study, including a small sample size and 2-week follow-up period. In comparison, our study had more participants and longer follow-ups. We also used logistic regression to examine the correlation, instead of Fischer's test.

Clinically, contrast runoff may not be present at the beginning of a neuroplasty and it may be necessary to adjust the catheter to observe contrast runoff. Contrast runoff was significantly correlated with a successful outcome; therefore, physical washout of inflammatory materials is necessary. Injection of local anesthetic and steroid can reduce the pain caused by mechanical pressure (10) and inflammatory responses (11,12). Racz et

Table 2. *Relationship between contrast spread pattern and outcome of procedure.*

	1 month		3 months		6 months		12 months	
	Fail	Success	Fail	Success	Fail	Success	Fail	Success
No contrast runoff	28 (70%)	12 (30%)	28 (70%)	12 (30%)	30 (75%)	10 (25%)	30 (75%)	10 (25%)
Contrast runoff	33 (25.6%)	96 (74.4%)	32 (24.8%)	97 (75.2%)	43 (33.3%)	86 (66.7%)	50 (38.8%)	79 (61.2%)
P	< 0.001*		< 0.001*		< 0.001*		< 0.001*	

*Indicates significant difference.

Table 3. *Relationship between contrast spread pattern and outcome of procedure in cases with foraminal stenosis.*

	1 month		3 months		6 months		12 months	
	Fail	Success	Fail	Success	Fail	Success	Fail	Success
No contrast runoff (N = 32)	26 (81.3%)	6 (18.8%)	24 (75%)	8 (25%)	24 (75%)	8 (25%)	24 (75%)	8 (25%)
Contrast runoff (N = 56)	13 (23.2%)	43 (76.8%)	13 (23.2%)	43 (76.8%)	20 (35.7%)	36 (64.3%)	23 (41.1%)	33 (58.9%)
P	< 0.001*		< 0.001*		< 0.001*		< 0.001*	

*Indicates significant difference.

Table 4. *Logistic regression results between contrast spread pattern and predicting successful epidural neuroplasty.*

Variable	1 month			3 months			6 months			12 months		
	B	OR (95% CI)	*P*	B	OR (95% CI)	*P*	B	OR (95% CI)	*P*	B	OR (95% CI)	*P*
Contrast runoff	1.915	6.788 (3.101-14.858)	< 0.001*	1.956	7.073 (3.225-15.514)	< 0.001*	1.792	6.000 (2.686-13.405)	< 0.001*	1.556	4.740 (2.133-10.534)	< 0.001*

B = regression coefficient, OR = odds ratio, CI = confidence interval. Logistic regression analysis was used.

al (13) recommended the infusion of local anesthetic, steroid, and hypertonic saline solution over 2 days. Continuous infusion not only insures safety but also produces a continuous flow of injectate at the site of the inflammatory response. The injectate reduces the inflammatory response, while the continuous flow washes inflammatory material away from the inflamed site, both of which produce successful outcomes (14).

Foraminal stenosis seen on MRI is an indication for surgical treatment of the cervical spine (15). An unsatisfactory surgical outcome might result from insufficient relief of the foraminal stenosis (15). Before visiting our clinic, 46 patients were recommended to have surgery, of whom 20 (43.5%) had successful outcomes; only 3 patients underwent surgical treatment after the cervical epidural neuroplasty. Cervical epidural neuroplasty is a good non-invasive treatment option before attempting surgical treatment.

Using an interlaminar approach during cervical epidural steroid injection, ventral epidural spread of contrast was achieved in 28% of the cases (16). The effectiveness of percutaneous adhesiolysis can be reduced by scar formation interfering with the spread of the injectate (17). However, the severity of epidural fibrosis is not correlated with pain or disability scores (18). While Moon et al (2) observed inferior outcomes in patients with foraminal stenosis, there was no correlation between foraminal stenosis and a poor outcome. Contrast runoff was seen in the fluoroscopic images of 63.6% of the patients with foraminal stenosis. Successful outcomes were more common in patients who showed contrast runoff compared with those who did not. We speculate that the flow of injectate through the neural foramen, which appears as contrast runoff, caused the preferable outcome of neuroplasty.

Conclusion

Cervical epidural neuroplasty with contrast runoff had a higher success rate than neuroplasty without contrast runoff, even in the presence of foraminal stenosis. The physical washout of inflammatory materials through the foramen is considered necessary for success. When performing cervical epidural neuroplasty, contrast runoff needs to be present to insure a successful outcome.

References

1. Manchikanti L, Abdi S, Atluri S, Benyamin RM, Boswell MV, Buenaventura RM, Bryce DA, Burks PA, Caraway DL, Calodney AK, Cash KA, Christo PJ, Cohen SP, Colson J, Conn A, Cordner H, Coubarous S, Datta S, Deer TR, Diwan S, Falco FJ, Fellows B, Geffert S, Grider JS, Gupta S, Hameed H, Hameed M, Hansen H, Helm S, 2nd, Janata JW, Justiz R, Kaye AD, Lee M, Manchikanti KN, McManus CD, Onyewu O, Parr AT, Patel VB, Racz GB, Sehgal N, Sharma ML, Simopoulos TT, Singh V, Smith HS, Snook LT, Swicegood JR, Vallejo R, Ward SP, Wargo BW, Zhu J, Hirsch JA. An update of comprehensive evidence-based guidelines for interventional techniques in chronic spinal pain. Part II: Guidance and recommendations. *Pain Physician* 2013; 16:S49-S283.
2. Moon DE, Park HJ, Kim YH. Assessment of clinical outcomes of cervical epidural neuroplasty using a Racz-catheter and predictive factors of efficacy in patients with cervical spinal pain. *Pain Physician* 2015; 18:E163-E170.
3. Park CH, Lee SH, Lee SC. Preliminary results of the clinical effectiveness of percutaneous adhesiolysis using a Racz catheter in the management of chronic pain due to cervical central stenosis. *Pain Physician* 2013; 16:353-358.
4. Oh CH, Ji GY, Cho PG, Choi WS, Shin DA, Kim KN, Kang HA. The catheter tip position and effects of percutaneous epidural neuroplasty in patients with lumbar disc disease during 6-months of follow-up. *Pain Physician* 2014; 17:E599-E608.
5. Racz GB, Heavner JE. Cervical spinal canal loculation and secondary ischemic cord injury — PVCS —perivenous counter spread — danger sign! *Pain Pract* 2008; 8:399-403.
6. Lee H, Nicholson LL, Adams RD, Maher CG, Halaki M, Bae SS. Development and psychometric testing of Korean language versions of 4 neck pain and disability questionnaires. *Spine (Phila Pa 1976)* 2006; 31:1841-1845.
7. Gerdesmeyer L, Wagenpfeil S, Birkenmaier C, Veihelmann A, Hauschild M, Wagner K, Muderis MA, Gollwitzer H, Diehl P, Toepfer A. Percutaneous epidural lysis of adhesions in chronic lumbar radicular pain: A randomized, double-blind, placebo-controlled trial. *Pain Physician* 2013; 16:185-196.
8. Heavner JE, Racz GB, Raj P. Percutaneous epidural neuroplasty: Prospective evaluation of 0.9% NaCl versus 10% NaCl with or without hyaluronidase. *Reg Anesth Pain Med* 1999; 24:202-207.
9. Park CH, Lee SH. Contrast dispersion pattern and efficacy of computed tomography-guided cervical transforaminal epidural steroid injection. *Pain Physician* 2014; 17:487-492.
10. Hayashi N, Weinstein JN, Meller ST, Lee HM, Spratt KF, Gebhart GF. The effect of epidural injection of betamethasone or bupivacaine in a rat model of lumbar radiculopathy. *Spine (Phila Pa 1976)* 1998; 23:877-885.
11. Brisby H, Byrod G, Olmarker K, Miller VM, Aoki Y, Rydevik B. Nitric oxide as a mediator of nucleus pulposus-induced effects on spinal nerve roots. *J Orthop Res* 2000; 18:815-820.
12. Murata Y, Onda A, Rydevik B, Takahashi K, Olmarker K. Distribution and appearance of tumor necrosis factor-alpha in the dorsal root ganglion exposed to experimental disc herniation in rats. *Spine (Phila Pa 1976)* 2004; 29:2235-2241.
13. Racz GB, Day MR, Heavner JE, Smith JP, Scott J, Noe CE, Nagy L, Ilner H. Epidural Lysis of Adhesions and Percutaneous Neuroplasty, Pain Management - Current Issues and Opinions (Ed). InTech 2012; DOI: 10.5772/39173. www.intechopen.com/books/pain-management-current-issues-and-opinions/epidural lysis-of-adhesions-and-percutaneous-neuroplasty
14. Lee F, Jamison DE, Hurley RW, Cohen SP. Epidural lysis of adhesions. *Korean J Pain* 2014; 27:3-15.
15. Tschugg A, Neururer S, Scheufler KM, Ulmer H, Thome C, Hegewald AA. Comparison of posterior foraminotomy and anterior foraminotomy with fusion for treating spondylotic foraminal stenosis of the cervical spine: Study protocol for a randomized controlled trial (ForaC). *Trials* 2014; 15:437.
16. Stojanovic MP, Vu TN, Caneris O, Slezak J, Cohen SP, Sang CN. The role of fluoroscopy in cervical epidural steroid injections: an analysis of contrast dispersal patterns. *Spine (Phila Pa 1976)* 2002; 27:509-514.
17. Manchikanti L, Singh V, Cash KA, Pampati V, Datta S. A comparative effectiveness evaluation of percutaneous adhesiolysis and epidural steroid injections in managing lumbar post surgery syndrome: A randomized, equivalence controlled trial. *Pain Physician* 2009; 12:E355-E368.
18. Coskun E, Suzer T, Topuz O, Zencir M, Pakdemirli E, Tahta K. Relationships between epidural fibrosis, pain, disability, and psychological factors after lumbar disc surgery. *Eur Spine J* 2000; 9:218-223.